



CLINICAL CASES

TROCHLEOPLASTY

SENSITIVE CONTENT

This document may contain violent or explicit content



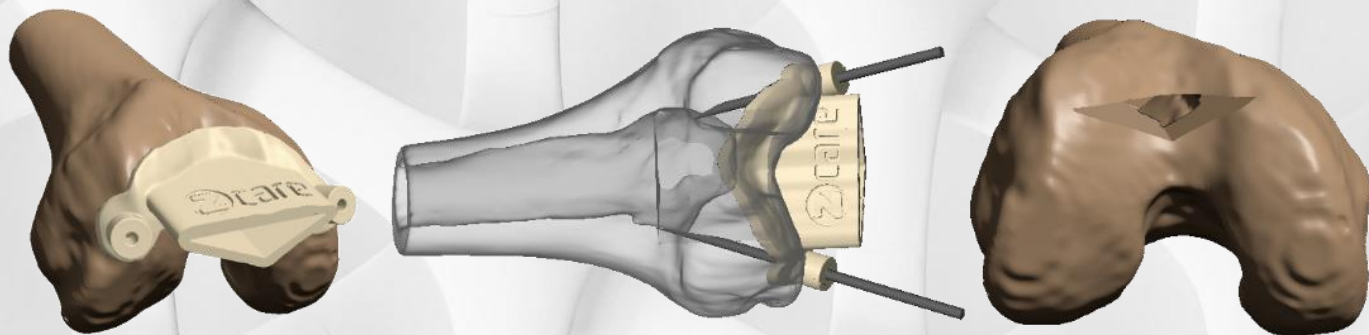www.zcare.tn

RECONSTRUCTION ASSISTED BY 3D MODELING

Surgeon Dr KHALIL AMRI
Hospital Main Military Hospital of Tunis

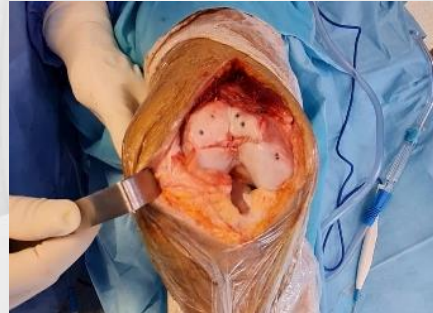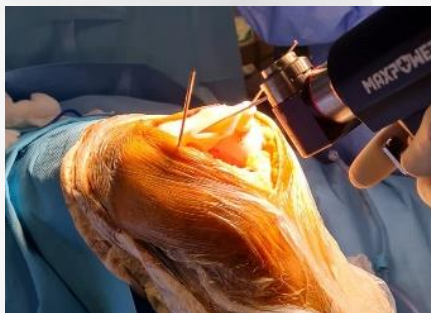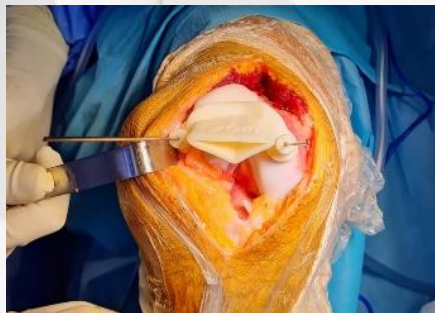PLANNING

The delineation was performed by Dr KHALIL AMRI, on the CT-scan and MRI was not needed.



SURGERY

Sulcus deepening trochleoplasty postoperative views. Patellar tilt and subluxation are corrected.

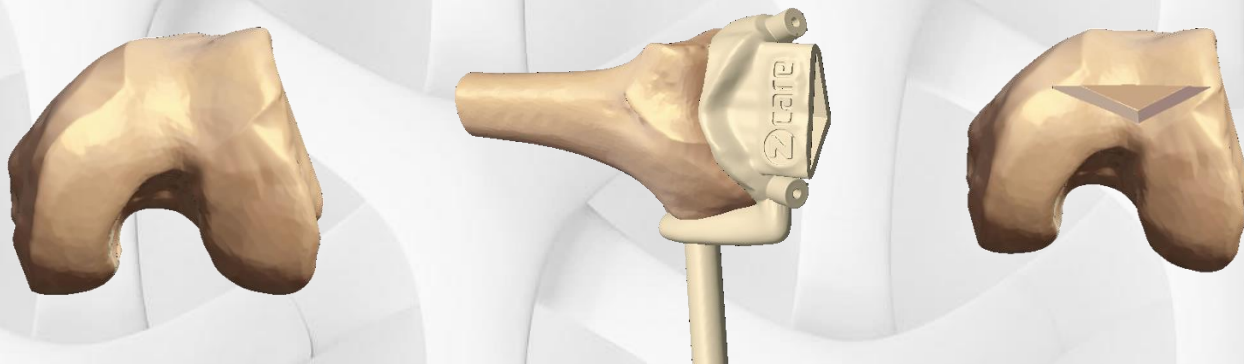


RECONSTRUCTION ASSISTED BY 3D MODELING

Surgeon **Dr KHALIL AMRI**
Hospital **Main Military Hospital of Tunis**

PLANNING

The delineation was performed by Dr KHALIL AMRI, on the CT-scan and MRI was not needed.



SURGERY

Sulcus deepening trochleoplasty postoperative views. Patellar tilt and subluxation are corrected.

