



CLINICAL CASES

SPACER MOLD

SENSITIVE CONTENT

This document may contain violent or explicit content



www.zcare.tn

RECONSTRUCTION ASSISTED BY 3D MODELING

Surgeon
Hospital

PR MONDHER MESTIRI
Mohamed-Kassab Institute of Orthopedics

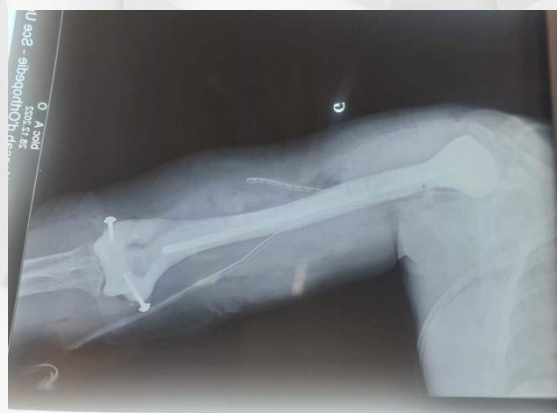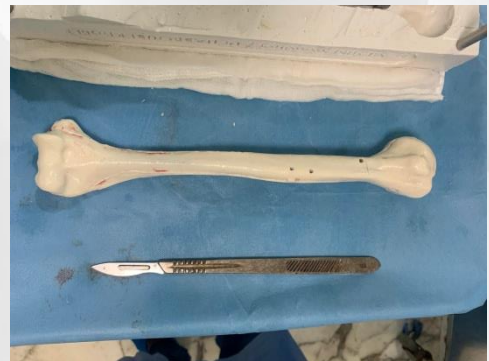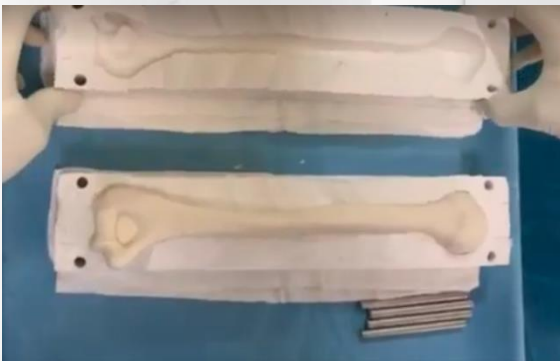PLANNING

The tumor delineation was performed by PR MONDHER MESTIRI, on the CT-scan and MRI was needed.



SURGERY

The implant is produced and placed into the humerus defect, perfectly complementing it.




RECONSTRUCTION ASSISTED BY 3D MODELING

Surgeon
Hospital

DR HASSAINI LASSAAD
SAHLOOL HOSPITAL OF SOUSSE

3D MODELS



CASE

The spacer is produced and placed into the HIP defect, perfectly complementing it.

